

ORIGINAL ARTICLE

A simple and practical method in treatment of ingrown nails: splinting by flexible tube

S Nazari*

Department of Dermatology, Istanbul Medical Faculty, Istanbul University, Istanbul, Turkey

Keywords

flexible tube, ingrown nail, splinting

*Corresponding author, Department of Dermatology, Istanbul Medical Faculty, Istanbul University, Istanbul, Turkey, tel. +90 212 5781059; fax +90 212 6146000; E-mail: s.nazari@yahoo.com

Received: 28 September 2005,
accepted 14 December 2005

DOI: 10.1111/j.1468-3083.2006.01793.x

Abstract

Background The ingrown nail (or onychocryptosis) is a common problem that occurs mostly in the big toe and causes high amounts of morbidity in affected patients. Many therapeutic methods have been described, most of them leading to severe damage to the nail or to frequent relapses. The nail splinting technique is a successful, simple and non-invasive therapeutic method for treating ingrown nails.

Objective To determine efficacy of the plastic tube insertion technique in patients with ingrown toenail and its use as a standard treatment.

Materials and Methods We encountered 32 cases (age range 9–67 years) of ingrown toenails in this clinical trial. All of the patients were treated using the plastic nail tube insertion technique for 7 to 15 days. Patients were examined daily for the first 3 days of treatment and were evaluated 3 and 6 months after treatment. All patients were followed up by a single observer.

Results Recurrence was seen in only two patients after 6 months of treatment (6.25%).

Conclusion The low recurrence rate using the nail splinting technique in the treatment of ingrown toenail, as well as its simple application, shows that this treatment constitutes an effective, non-invasive method. It appears that this technique can substitute other more invasive surgical methods, particularly in the early stages of this disease.

Introduction

The ingrown nail, *unguis incarnatus*, is a common condition that is frequently seen among adolescents and young adults, with a male predominance. It results from various aetiologies including poorly fitting shoes, improper trimming of the nail, chronic trauma and excessive external pressure.^{1,2} The penetrating nail edge induces an inflammatory response that can result in local growth of granulation tissue, and sometimes infection. Patients usually initially present with pain in the lateral or medial fold of the great toes but, with progression, drainage, infection, and difficulty in walking occur. Many invasive approaches such as classic wedge excision and partial matrix phenolization have evolved for ingrown nails, but these surgical therapeutic modalities have had many disadvantages, such as a prolonged wound healing period,

scarred and deformed nail production, or the restriction of normal activities.^{1,3–5,13,16,22,26,28} In recent years, non-invasive conservative treatments have evolved as feasible treatments, challenging the more traditional surgical treatments.^{6–9,11,32}

Nail splinting by a flexible tube is a non-invasive therapeutic method for treating ingrown nails. This method is simple and easy to perform and does not require any special equipment. After inserting the tube, the patient experiences instant pain relief and can return to normal activities immediately. Although the therapeutic effects of the nail splinting technique are known, few studies have been published concerning the recurrence rate of this method.^{6–9,11,18} In this study, effectiveness of the nail splinting technique by plastic tube insertion is evaluated and re-assessed as a classic therapy for patients with onychocryptosis.

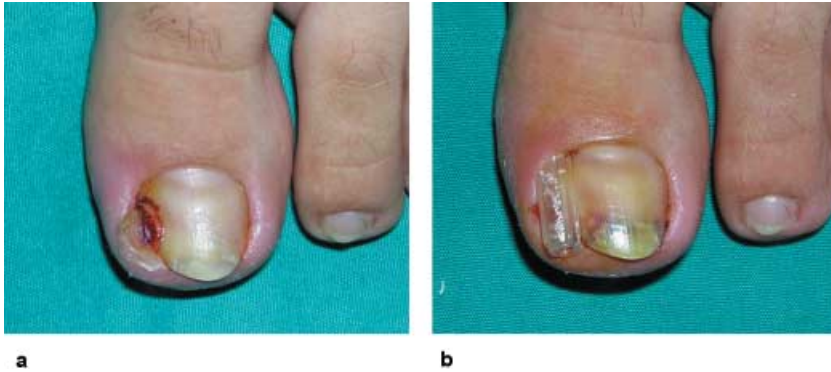

fig. 1 (a) Ingrown nail with granulation tissue. (b) Splinting the ingrown edge with the plastic tube after removing the excessive tissue.

Materials and methods

A prospective study on the nail splinting technique was carried out in 32 patients with ingrown toenail (21 male and 11 female patients) with a mean age of 29.3 years (age range 9–67) between April 2004 and February 2005. Patients were classified into three stages according to tissue status and level of pain (Table 1).

All patients were examined daily for the first 3 days of treatment and evaluated for proper position of splint, tissue status and level of pain. After 3 and 6 months all patients were re-evaluated in order to determine recurrence. Recurrence was defined as the presence of symptomatic nail ingrowth within 6 months of treatment.

The procedure was based on the technique of Ilfeld *et al.*¹⁰ After cleaning the nail and adjacent tissue with an

antiseptic, the area was anaesthetized by local, subcutaneous administration of 1–2.5% lidocaine without epinephrine. A topical anaesthetic (Emla cream®, AstraZeneca, Istanbul, Turkey) was used as an alternative for patients who did not accept the local injection. The excessive granulation tissue, if present, was carefully removed with a curved mosquito or a scalpel blade, and bleeding was controlled by direct pressure. Sharp nail edge that had penetrated and injured underlying soft tissues was trimmed and separated from adjacent tissue using a curved haemostat. A plastic cap of a small-sized needle (29 G) of insulin injectors was used as a splint because of its flexibility and because it was easily obtainable. The plastic tube was incised according to the length of the nail edge and was placed on the nail edge by pushing proximally so that the lateral nail edge was totally covered by the splint (fig. 1), and was then attached with a bandage.

There was no restriction on normal activities while the splint was in place. Patients were examined, the splint removed slowly, and both the splint and the area were cleaned and the splint gently put in place again daily by a physician for 3 days. After this time, patients were advised to keep splints in place all through the day until there was no sign or symptom in the area including pain, swelling, erythema and exudation (7–15 days in this study) (fig. 2).

Table 1 Stages of involvement

Stage	Tissue status	Pain
0	Normal tissue (no symptoms)	None
1	Erythema and oedema	Little
2	Stage 1 + exudation	Disturbing
3	Stage 2 + granulation tissue	Frustrating

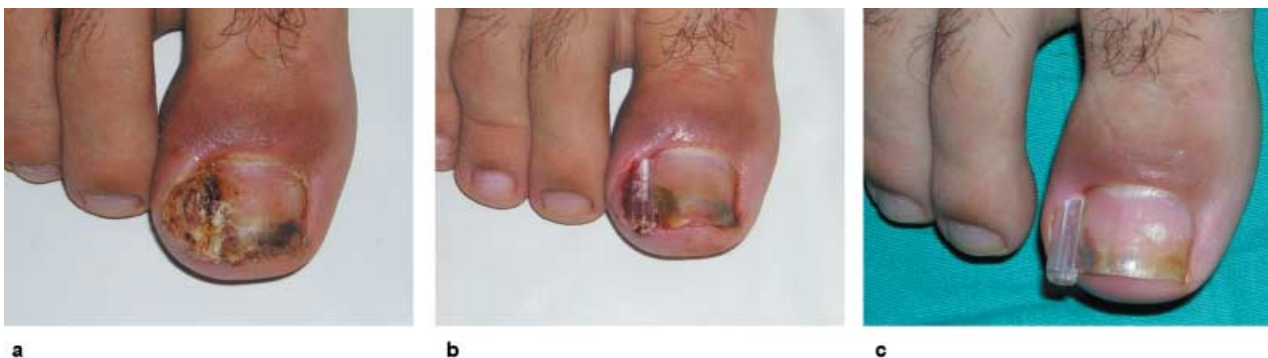

fig. 2 (a) An ingrown nail with severe granulation tissue. (b) Removing the granulation tissue and splinting. (c) Eleven days after treatment. There is neither pain nor erythema and exudation.

During this period of time, the splint was removed every night and was placed again throughout the day.

As a measurement of nail involvement, each stage was assigned a score as follows: stage 0 corresponded to 0 points; stage 1, 10 points; stage 2, 20 points; and stage 3, 30 points.

Results

The subjects in this study were 32 patients on whom the nail splinting technique was performed from April 2004 to February 2005. The improvement rate and recurrence rate was assessed.

The mean scores indicating the degree of the involvement (0–30 scores) were 21.25 before treatment, 0.31 3 months after treatment, and 0.93 six months after treatment. The improvement rate was 99% after 3 months and 95.9% after 6 months. The mean scores of pretreatment and post-treatment stages (both 3 and 6 months after treatment) were significantly different ($P < 0.05$) (fig. 3). Therefore this technique made statistically significant improvement 3 and even 6 months after treatment.

During this study, there were two recurrences out of a total of 32 patients after 6 months; overall recurrence rate being 6.25%. One of these patients was a 21-year-old man who was a professional sportsman (footballer), and the other was a 19-year-old, female hostess.

Discussion

Ingrown toenail is induced by excessive external pressure such as tight footwear, improper nail trimming, trauma, and incurvated nails, among other factors. Pain and inflammation are usually the result of nail edge penetration into the

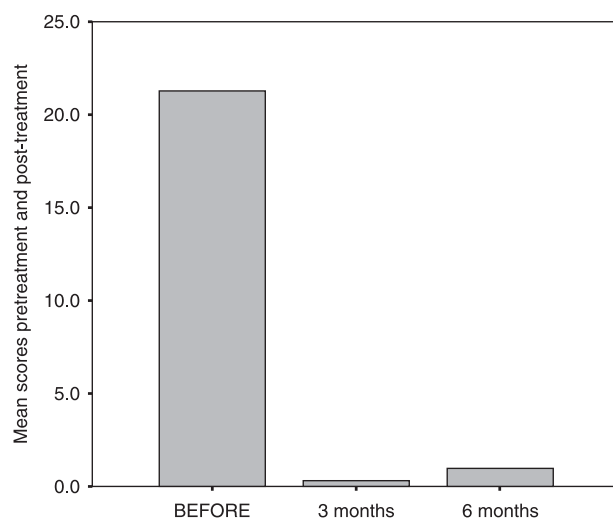


fig. 3 The mean scores of nail involvement before, and 3 and 6 months after treatment.

soft tissues, which causes a foreign body-like reaction. Traumatized soft tissues produce granulation that grows over the edge of the nail.^{1,2} Therefore, it is important to restore the normal balance between the nail and the adjacent tissue. The usual treatment involves removal of the granulation and preservation of the normal nail; thus the granulation can very quickly cover the nail groove again.¹² Water soaks and antibiotics are common approaches to calm the inflammatory response of ingrowing nails, but these approaches are often ineffective.

Many surgical techniques are available for the treatment of ingrowing toenails. An ideal technique is expected to possess the following features: applicable under local anaesthesia, technically uncomplicated, quick healing, having no or near zero recurrence rate, cosmetically acceptable, not expensive, and non-invasive as far as possible.

As a conventional treatment modality, partial or total nail avulsion has been widely used, but has resulted in high recurrence rates (42 to 83%).^{4,13–15} Wedge resection is also associated with high recurrence rates of 13 to 33%.^{3,16–19} These procedures are difficult and remarkably invasive surgical techniques, with a prolonged healing time, considerable pain and frequent postoperative infectious complications.^{13–19} Partial matricectomy with cryotherapy or laser is associated with high cure rates of 93.3% for the former, and 100% for the latter method.^{20,21} These procedures are new modalities and require the establishment of long-term results in large series. In addition, these techniques are relatively expensive and invasive, and require equipment.

Matrix cauterization with phenol has a low recurrence rate of 0 to 11%, and has been the preferred method in recent years. Extensive and unpredictable tissue damage, excessive drainage, and prolonged healing (up to 6 weeks) are reported be the drawbacks of this technique, which occur as a result of coagulation necrosis of the surrounding tissues, and an inflammatory response.^{16,17,22–27} In addition, phenol is a caustic agent that can lead to chemical burns and should be used with caution.²⁸

These complications seen after invasive surgical treatments have prompted physicians to try another method that is safer, cheaper, more practical, non-complex, and non-invasive.

Ingrown toenails can be quickly and effectively treated in outpatient settings using the nail splinting technique. This technique is effective, non-invasive, practical, cosmetically favourable and non-cicatricial, and should be considered as a first-line treatment for all uncomplicated ingrowing toenails. This method has been continuously developed since Newman²⁹ first introduced it in 1949, using tops of pineapple cans. Sivitz³⁰ and Mogull³¹ used acrylic resins and methyl methacrylate, respectively, as a buffer between the nail and soft tissues. Ilfeld and August¹⁰ used a Teflon plastic strip. Wallace *et al.*¹⁸ introduced the gutter treatment, and Schulte *et al.*⁸ and Kim *et al.*¹¹ used

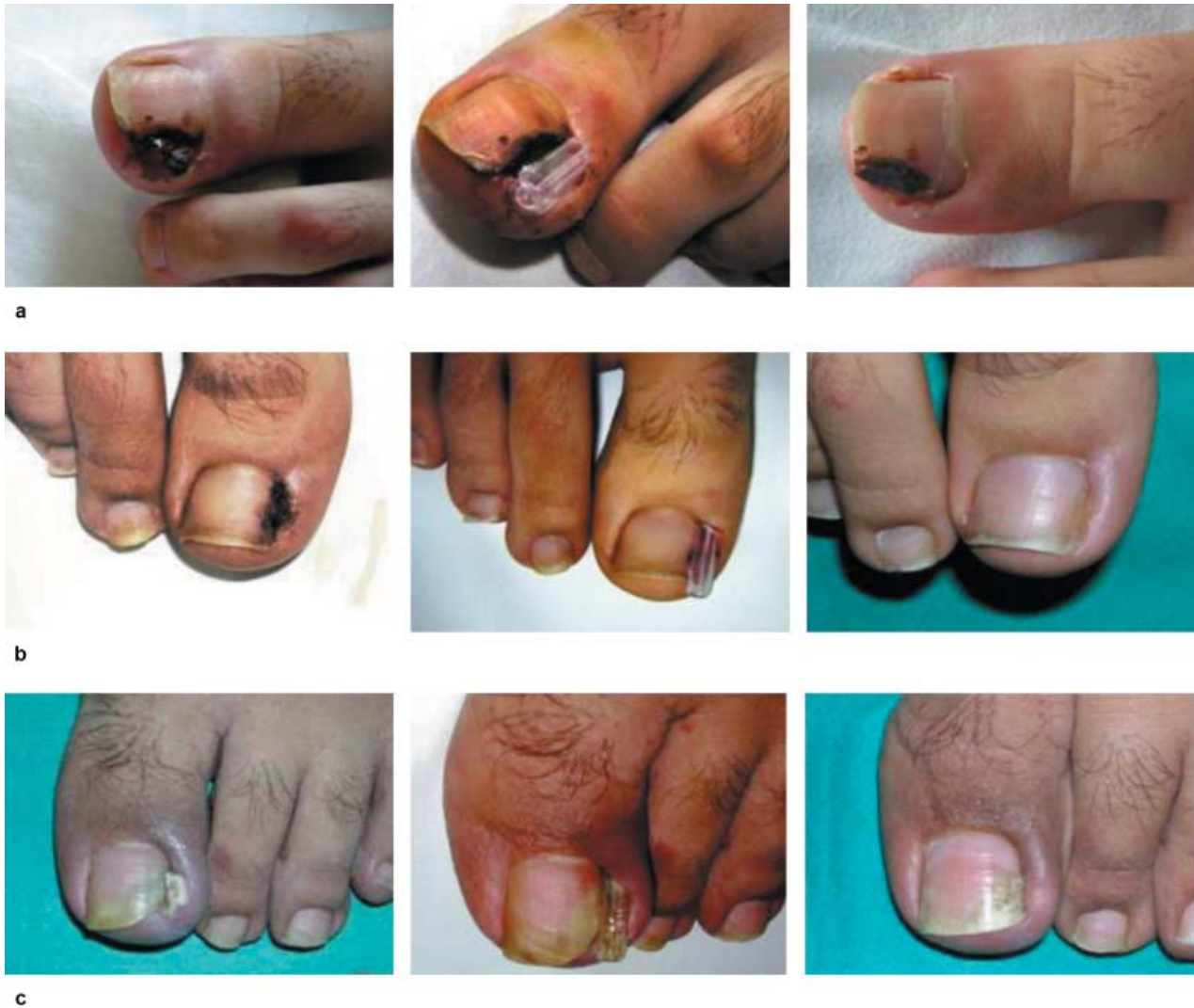

fig. 4 Samples of ingrown nails treated with the splinting method. (a) A 21-year-old, female medical student, who had been suffering from ingrown toenail for a year. Nail avulsion and other treatment modalities such as silver nitrate applications had not resolved the problem. (b) A 17-year-old student with a recurrent ingrown nail problem. (c) This 45-year-old man was the husband of a nurse; he had tried nail avulsion two times before this treatment.

a flexible tube in a similar way to us, but they did not anaesthetize the area, except in cases of severe, painful lesions, and patients with granulation tissue. Pottie *et al.*³² treated ingrowing nail using cotton wicks in the nail sulcus. Although the materials used in the nail splinting technique differed, the principle remains the same: that is, separating the nail plate from the soft tissue so as to provide a channel for the nail to grow.

The removal time of the splint and the recurrence rate of this technique vary considerably among different reports. The first time this procedure was performed, Newman²⁹ removed the pineapple can after 3 weeks. In the study by Wallace *et al.*¹⁸ the gutter was removed 8–12 weeks after the initial procedure and the recurrence rate was 44–48%. He reported that the gutter should be retained for at

least 10 weeks to reduce the recurrence rate. Schulte *et al.*⁸ introduced the flexible tube and treated 62 patients with ingrowing nails. The area was washed daily for 3 to 4 weeks. Gupta *et al.*,⁶ and later Kim *et al.*,¹¹ used a flexible plastic tube from scalp vein sets. Kim *et al.*¹¹ showed that if there was no anatomical deformity or large defects in the nail, the splint could be removed as early as at 3 days. The recurrence rate in this study was 8.7%.

Our study was technically similar to the study of Kim *et al.*¹¹ but a plastic cap of a small-sized needle (29 G) of insulin injectors was used instead of scalp vein sets as the splint, because it was easily incised as required, as well as being consistent and obtainable. Unlike in Kim *et al.*'s study, local anaesthesia was used in all of the patients, because the pain of the procedure could be disturbing to patients.

The splint was removed when the patient had no symptoms and no redness, oedema, or exudation in the area was observed. The recurrence rate in our study was 6.25% and occurred in two out of the total 32 patients. Both of these recurrences were in the young age group who had active professional occupations in which their feet were suffering from chronic trauma. Therefore, if the nail is intact or has minor defects, and if the patient is careful to protect the area from excessive external traumas, even splinting for a short time – although not as short as 3 days as in Kim *et al.*'s study¹¹ – will be sufficiently effective (fig. 4). Patients should be advised about nail trimming and proper footwear.

In conclusion, it is suggested that the simple and practical method used in this study can be used as a first-line therapy for patients with onychocryptosis with or without granulation tissue. During this treatment technique, onychocryptosis, as well as granulation tissue, was effectively cured without any destructive outcomes in nail matrix. The results obtained in this study and other similar studies are promising.

Acknowledgements

I would like to acknowledge Prof. Gülsevım Azizlerli and Prof. Güzin Özarmagan, Department of Dermatology, Istanbul Medical Faculty, Istanbul University, for their continuous support, valuable suggestions, and encouragement during this study.

References

- Ikard RW. Onychocryptosis. *J Am Coll Surg* 1998; **187**: 96–102.
- Heifetz CJ. Ingrown toe-nail: a clinical study. *Am J Surg* 1937; **38**: 298–315.
- Fulton GJ, O'Donohoe MK, Reynolds JV, Keane FBV, Tanner WA. Wedge resection alone or combined with segmental phenolisation for the treatment of ingrowing toenail. *Br J Surg* 1994; **81**: 1074–1075.
- Murray WR, Bedi BS. The surgical management of ingrowing toenail. *Br J Surg* 1975; **62**: 409–412.
- Seigle R, Stewart R. Recalcitrant ingrowing nails. *J Dermatol Surg Oncol* 1992; **18**: 744–752.
- Gupta S, Sahoo B, Kumar B. Treating ingrown toenails by nail splinting with a flexible tube: an Indian experience. *J Dermatol* 2001; **28**: 485–489.
- Robertson DG, Parker PJ. The treatment role of the plastic nail guard for ingrowing toenails. *J R Army Med Corps* 2001; **147**: 183–186.
- Schulte KW, Neumann NJ, Ruzicka T. Surgical pearl: nail splinting by flexible tube. A new non-invasive treatment for ingrown toenails. *J Am Acad Dermatol* 1998; **39**: 629–630.
- Lazar L, Erez I, Katz S. A conservative treatment for ingrown toenails in children. *Pediatr Surg Int* 1999; **15**: 121–122.
- Ilfeld FW, August W. Treatment of ingrown toenail with plastic insert. *Orthop Clin North Am* 1974; **5**: 95–97.
- Kim YJ, Ko JH, Choi KC, Lee CG, Lim KJ. Nail-splinting technique for ingrown nails: the therapeutic effects and the proper removal time of the splint. *Dermatol Surg* 2003; **29**: 745–748.
- Zechel G. The fallacy of the ingrown nail. *Surg Gynecol Obstet* 1970; **131**: 117–118.
- Greig JD, Anderson JH, Ireland AJ, Anderson JR. The surgical treatment of ingrowing toenails. *J Bone Joint Surg* 1991; **73**: 131–133.
- Lloyd-Daveis RW, Brill GC. The aetiology and out-patient management of ingrowing toenails. *Br J Surg* 1963; **50**: 592–597.
- Sykes PA, Kerr R. Treatment of ingrowing toenails by surgeons and chiropodists. *Br Med J* 1988; **297**: 335–336.
- Issa MM, Tanner WA. Approach to ingrowing toenails: the wedge resection/segmental phenolisation combination treatment. *Br J Surg* 1988; **75**: 181–183.
- van Der Ham AC, Hackeng CAH, Yo TI. The treatment of ingrowing toenails. *J Bone Joint Surg* 1990; **72**: 507–509.
- Wallace WA, Milne DD, Andrew T. Gutter treatment for ingrowing toenails. *Br Med J* 1979; **2**: 168–171.
- Robb JE. Surgical treatment of ingrowing toenails in infancy and childhood. *Z Kinderchir* 1982; **36**: 63–65.
- Silverman SH. Cryosurgery for ingrowing toenails. *J Roy Coll Surg Edinb* 1984; **29**: 289–291.
- Leshin B, Whitaker DC. Carbon dioxide laser matricectomy. *J Dermatol Surg Oncol* 1988; **14**: 608–611.
- Bostanci S, Ekmekci P, Gurgey E. Chemical matricectomy with phenol for the treatment of ingrowing toenails: a review of the literature and follow-up of 172 treated patients. *Acta Derm Venereol* 2001; **81**: 181–183.
- Gem MA, Sykes PA. Ingrowing toenails: studies of segmental chemical ablation. *Br J Clin Pract* 1990; **44**: 562–563.
- Young MRA, Rutherford WH. Re-operation rate for ingrowing toenail treated by phenolisation: 3-year follow-up. *Br J Surg* 1987; **74**: 202–203.
- Cameron PF. Ingrowing toenails: an evaluation of two treatments. *Br Med J* 1981; **283**: 821–822.
- Varma JS, Kinninmonth AWG, Hamer-Hodges DW. Surgical wedge excision versus phenol wedge cauterization for ingrowing toenail. *J Roy Coll Surg Edinb* 1983; **28**: 331–332.
- Rounding C, Bloomfield S. Surgical treatments for ingrowing toenails (Cochrane Review). The Cochrane Library, Oxford, 2002.
- Sugden P, Levy M, Rao GS. Onychocryptosis-phenol burn fiasco. *Burns* 2001; **27**: 289–292.
- Newman RW. A simple treatment of ingrown toenail. *Surg Gynecol Obstet* 1949; **89**: 638–639.
- Sivitz SC. A preliminary report on the use of self-cutting plastic resins in nail groove therapy. *J Natl Assoc Chirop* 1953; **43**: 34–39.
- Mogull P. Uses of methyl methacrylate in the treatment of inverted nails. *J Natl Assoc Chirop* 1954; **44**: 35.
- Pottie K, Dempsey M, Czarnowski C. Practice tips. Toenail splinting. *Can Fam Physician* 2003; **49**: 1451–1453.